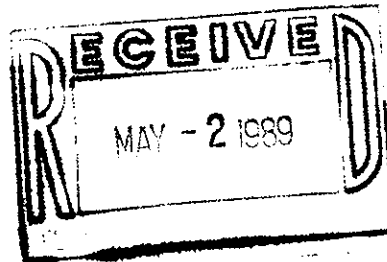


HARPER COUNTY

COURT HOUSE - ANTHONY, KANSAS 67003 - 316-842-5264

HEALTH DEPARTMENT
and
HOME HEALTH AGENCY



April 26, 1989

Southwest Technologies, Inc.
1510 Charlotte
Kansas City, MO 64108

Dear Angela Stout,

A client was referred to Harper County Home Health 05-19-87. The client was 58 years old and she was a Diabetic with severe complications of Diabetic Neuropathy. Charot joint with infected Planter Neuropathic ulcer. She wore a rigid plastic brace.

The Neuropathic ulcer was resistant to healing due to callous formation with subsequent ulcer formation under the callous. 10-05-88, we started using Elasto-Gel in the treatment of Neuropathic ulcer. The ulcer was healed on 11-23-88.

The RN with the assistance from the RPT designed a pattern for a .25" Elasto-Gel pad which was to be covered by a 4 way stretch material and used as a cushion in the ankle foot brace. This pad was placed in the brace 11-23-88. There has been no callous build up since 01-25-89.

The Elasto-Gel dressing gave the client more comfort than other treatments. She continues to use the two pads alternating the two pads. We do not have a moisture problem with the Elasto-Gel covered pad. This occlusive dressing has all the qualities we like, see thru, non adhesive to the wound, absorbs drainage, and is easy to remove.

The Southwest Technologies, Inc., placed a non skid material on the bottom of the Elasto-Gel pad which helped to keep the pad in the brace and in place.